

# Humeral shaft fractures with neurological deficit in major trauma

Alessandra Maresca<sup>1</sup>, Letizia Guerrini<sup>2</sup>, Raffaele Pascarella<sup>1</sup>

<sup>1</sup> Orthopaedic and Traumatology Department, University Hospital Company Torrette, Ancona, Italy; <sup>2</sup> Orthopaedic Clinic, University Hospital Company Torrette, Ancona, Italy

## SUMMARY

**Objective.** The objective of this article is to describe how to manage the humeral shaft fractures with neurological involvement in emergency trauma. Traumatic humeral fractures can be associated with neurological palsy in 11.6-23% <sup>1</sup> of cases and the most frequent involvement is the radial nerve. The median and ulnar nerves are usually damaged directly from trauma with an open humeral fracture. In contrast, the radial nerve is associated with closed fractures and the palsy is caused from dislocation of bone fragments.

**Methods.** We report our protocol for management of humeral shaft fractures with neurological involvement that consists in early nerve exploration, reduction, and bone fixation. In the presence of an open fracture, this approach is mandatory as soon as possible, and within six hours from the trauma, and is performed by stabilization with an external fixator. In case of a closed fracture with neurological palsy, the operation can be performed within 12 hours and involves internal fixation with a plate. Surgically treatment of these humeral shaft fracture should be early together with nerve exploration because it can be entrapped or skewered in the fracture site. Very rarely have we observed complete or incomplete dissection of the radial nerve.

**Conclusions.** In open fractures with neurological deficits, early stabilization with an external fixator is mandatory, as well as repair of the vascular damage when present with a vascular surgeon and careful exploration of the affected nerve with a plastic surgeon or micro surgeon. In closed fractures with radial nerve paralysis, we believe that immediate exploration, within 12 hours, and rigid osteosynthesis with a plate is the correct approach.

**Key words:** humeral fractures, shaft, radial nerve, nerve palsy, trauma

Received: March 2, 2023

Accepted: April 14, 2023

## Correspondence

Alessandra Maresca

Orthopaedic and Traumatology Department, University Hospital Company Torrette, via Concio 17/b, 60021 Camerano (AN), Italy

E-mail: alexandre\_m@libero.it

**How to cite this article:** Maresca A, Guerrini L, Pascarella R. Humeral shaft fractures with neurological deficit in major trauma. Lo Scalpello Journal 2023;37:35-41. <https://doi.org/10.36149/0390-5276-277>

© Ortopedici Traumatologi Ospedalieri d'Italia (O.T.O.D.I.) 2023



OPEN ACCESS

This is an open access article distributed in accordance with the CC-BY-NC-ND (Creative Commons Attribution-NonCommercial-NoDerivatives 4.0 International) license. The article can be used by giving appropriate credit and mentioning the license, but only for non-commercial purposes and only in the original version. For further information: <https://creativecommons.org/licenses/by-nc-nd/4.0/deed.en>

## Introduction

Traumatic humeral fractures can be associated with neurological palsy in 11.6-23% of cases <sup>1</sup>. The most frequent involvement is the radial nerve, followed by the ulnar and median nerves in 1.6-3% of cases <sup>1</sup>. In open fractures or fractures with penetrating injuries, complete traumatic or incomplete nerve sectioning can be observed. Most often these lesions correspond to neurapraxias related to direct trauma or distraction related to fracture dislocation.

Different injuries can be observed depending on the type of fracture and site. Proximal humeral fractures, and above all dislocated fractures of the proximal third, may be associated with complete brachial plexus palsy and not individual nerve palsy <sup>1-3</sup>. These fractures must be treated early only in presence of a dislocation which could compress plexus, otherwise the treatment can be delayed. Plexus paralysis is often permanent, and neurological recovery is poor in patients who undergo repair, regardless of whether it was acute or delayed. Altogether, these findings highlight the severe neurologic morbidity associated with this injury <sup>4</sup>. Shaft and distal third humeral fractures can be associated with radial nerve palsy, with the most frequent involvement in 10-20% of cases <sup>1</sup>. Median or ulnar nerve lesion is rare and seen in 1.6-3% of cases <sup>1</sup>.

In these patients, the injury usually affects an open fracture or penetrating trauma.

### Median nerve palsy

These injuries, as mentioned, are very rare, usually related to an open fracture involving the anterior region of the arm in the distal middle third. The nerve is dissected or damaged by direct penetrating trauma rather than fracture displacement. Vascular damage has an incidence of 0.5-3%<sup>1</sup> and severe soft tissue impairment may also be present. Baseline diagnosis consists in two-projection humeral X-rays associated with a contrast-enhanced CT scan of the arm, in case of suspected vascular lesion or severe soft tissue damage. Surgical treatment must be immediate and includes fracture stabilization, vascular repair if present, nerve exploration and soft tissue coverage. In clinical examination, the patient reports an area of dysesthesia or anesthesia in the middle part of the hand and third finger. A thorough range of motion assessment may be more difficult due to pain and functional limitation caused by the fracture, but deficits in finger flexion are present.

### Ulnar nerve palsy

These injuries are extremely rare<sup>1</sup> usually related to an open fracture involving the medial region of the arm in the middle third of the shaft or from direct trauma of distal humerus fractures. In these lesions, like median nerve involvement, we proceed with baseline instrumental investigations that consist in two-projection humeral X-rays associated with contrast-enhanced CT scan of the arm, in case of suspected vascular lesion or severe soft tissue damage. Surgical treatment must be performed early with fracture stabilization, vascular repair if present, nerve exploration and soft tissue coverage. In paralysis associated with a closed distal humerus fracture, we believe there is no indication for early operative treatment because in most cases the ulnar nerve is damaged by direct trauma and is never dissected or incarcerated at the fracture site. In clinical examination, the patient reports an area of dysesthesia or complete anesthesia of the 4<sup>th</sup> and 5<sup>th</sup> finger and the medial border of forearm. A complete range of motion assessment may be difficult due to algic functional limitation caused by the fracture. The main motor loss that occurs is the deficit of finger abduction and extension above the metacarpophalangeal joint.

### Radial nerve palsy

Radial nerve palsy is the most common lesion associated with humeral shaft fractures with an incidence of 4-16%<sup>5,6</sup> and 20.7% are associated with a distal humeral fracture.

Palsy is usually due to a nerve strain caused by displaced fracture or resulting deformity of the upper limb. It can be associated with an open fracture involving the posterior or lateral region of the arm in the distal middle third. For diagnosis, the same indications mentioned above apply: trauma projection

X-rays of the humerus associated with a contrast-enhanced CT scan of the arm, in case of suspected vascular lesion or severe soft tissue damage. The treatment of these lesions is much debated in the literature. There are those in favor of surgical intervention with radial nerve exploration<sup>5-7</sup> and those who encourage expectant management. Advocates of delayed surgical intervention claim that neurological recovery is not related to exploration, but is spontaneous being in most cases neurapraxia<sup>3,4</sup>. Our opinion is that a humerus fracture associated with neurological paralysis must be surgically treated early or in any case within 12 hours of the traumatic event. This is because, although rare, the nerve can be trapped on fracture fragments or dissected, and early treatment may be more effective than late treatment. Indeed, early exploration in our opinion, allows for characterization of nerve injury and treatment together with fracture stabilization and avoid late nerve incarceration. Furthermore, early exploration permits repair that is expressed in a less motor endplate loss and less muscular atrophy, which can lead to quicker nerve recovery and return to function<sup>6</sup>. The purpose of this publication is to discuss a management strategy for all kinds of humeral fractures with complete sensor and motor nerve palsy.

## Discussion

Traumatic humeral fractures can be associated with neurological palsy in 11.6-23 % of cases<sup>1</sup>. The most frequent involvement is the radial nerve<sup>1,6</sup>, followed by the ulnar and median nerve in 1.6-3% of cases<sup>1</sup>.

Median and ulnar nerve palsy are usually associated with open fractures or severe soft tissue damage. The nerve is then often dissected, stretched, or severely damaged. Sometimes there may be vascular lesions (0.5-3%)<sup>1</sup>. In these cases, the treatment is managed by a multidisciplinary team. The diagnosis is performed with contrast-enhanced CT to identify the interruption point or vessel closure. The fracture must be stabilized with an external fixator, vascular damage repaired, the nerve explored, and then bone and noble tissues covered with soft tissues. Neurological recovery is highly variable with an average of 77-100% depending on the type of lesion<sup>8</sup>. Radial nerve palsy is the most common lesion associated with closed humeral fractures of the distal middle third<sup>1</sup>.

Significant controversy persists regarding management of a radial nerve palsy associated with a closed humeral shaft fracture<sup>4-6,8</sup>. In the presence of an open fracture, there are very little controversy and early exploration is the widely accepted standard of treatment<sup>9</sup>.

Currently, non-controversial and well-accepted indications of early radial nerve exploration in humeral fracture in the literature are: irreducible fractures, associated vascular lesions, high energy trauma, piercing wound, high-velocity gunshot, radial nerve palsy after manipulation, Holstein Lewis fractures and open fracture as mentioned above<sup>9-11</sup>.

**Table I. Biso GMNR (from Munakomi S. Neuroanatomy, neurapraxia. [Updated 2022;Oct 24]. In: StatPearls [Internet]. Treasure Island, FL: StatPearls Publishing 2022, mod.).**

Seddon	Sunderland	Injury	Spontaneous recovery	Nerve conduction study	Electromyography
Neurapraxia	Grade I	Focal segmental demyelination	Yes	Partial/complete conduction block proximally. Preserved conduction block distally even after 2 weeks	Normal morphology and poor MUAP recruitment
Axonotmesis	Grade II	Damaged axon with intact endoneurium	Yes, slower than neurapraxia	Partial/complete conduction block proximally. Preserved conduction block distally until Wallerian degeneration sets in	Abnormal activity
Axonotmesis	Grade III	Damaged axon and endoneurium with intact epineurium	Not very likely, surgical intervention may be needed		
Axonotmesis	Grade IV	Damaged axon, endoneurium and perineurium with intact epineurium	Highly unlikely, surgical intervention is necessary		
Neurotmesis	Grade V	Complete nerve transection (disruption of myelin sheath, axon, endoneurium, perineurium and epineurium)	No, surgical intervention is necessary	Complete conduction block proximally and distally	Abnormal activity

For closed fractures, the literature is divided. Conservative treatment is preferred by some authors<sup>12</sup> and especially in middle third shaft humeral fractures because of the presence of interposed soft tissues between bone and the radial nerve. Furthermore, advocates of delayed surgical intervention support the high percentage of spontaneous healing, the definition of nerve damage that is easier to repair highlighted by the thickening of the neurilemmal sheath and the lack of surgical risks. There are authors who suggest the use of intramedullary devices for definitive treatment without nerve exploration arguing that in most cases the radial nerve recovers in 4-6 months<sup>11,13,14</sup>.

Others suggest early surgical nerve exploration and open reduction and internal fixation (ORIF), especially in distal third humeral fractures where the radial nerve is close to bone in the lateral intermuscular septum with risk of entrapment<sup>15-17</sup>.

The potential advantages of early nerve exploration are that it allows a more careful diagnosis, better nerve injury characterization and repair, and thus less muscular atrophy and endplate loss. This avoids the possibility of nerve entrapment into tissue scars or bone callus. It also reduces the risk that the nerve may become lacerated or spread by a bone fragment moving radially and proximally.

Most of these authors speak about nerve recovery, but do not point out about what types of fractures they treat conservatively, or the type of immobilization, or for how long the patient must rest for the fracture to heal.

The choice of treatment as mentioned above, depends on various factors including the localization, fracture type, and type of nerve lesion<sup>18-20</sup>.

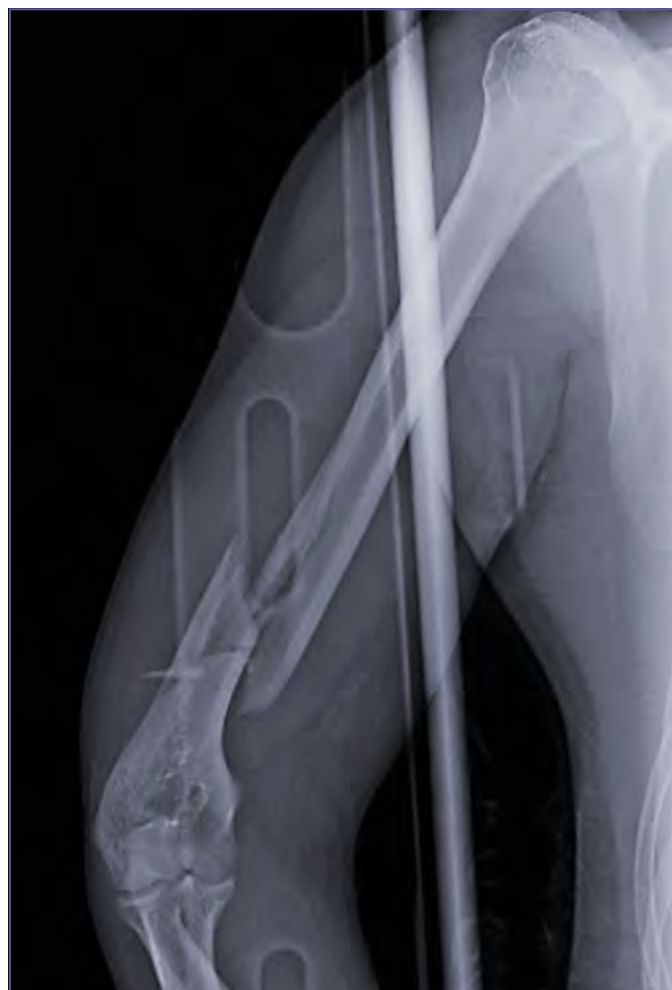Regarding anatomy, the radial nerve is a greater risk for injury along the distal third of the humerus due to the absence of

interposed muscular protection. At this level, the nerve is high to the bone and pierces the lateral intermuscular septum 10 cm above the lateral epicondyle<sup>21</sup>.

Furthermore, the type of fracture and extent of displacement affect radial nerve involvement. Indeed, several studies have demonstrated that transverse and spiral fractures are most commonly involved in radial nerve lesions<sup>7,22,23</sup>.

Regarding the nerve type, Sunderland's classification can be used<sup>19</sup>. Types III, IV, and V are found in conjunction with high energy trauma, with displaced and/or unstable fractures in which there is a risk of a continuous or tear injury (Tab. I). Surgical fracture treatment must exclude CRIF solutions such as MIPO, nailing, and external fixation to avoid iatrogenic injuries to nerve structures.

After surgery nerve recovery must be monitored, performing complete physical examination that consists of sensory and motor evaluation of the ulnar, median, and radial nerves along with electrodiagnostic study.



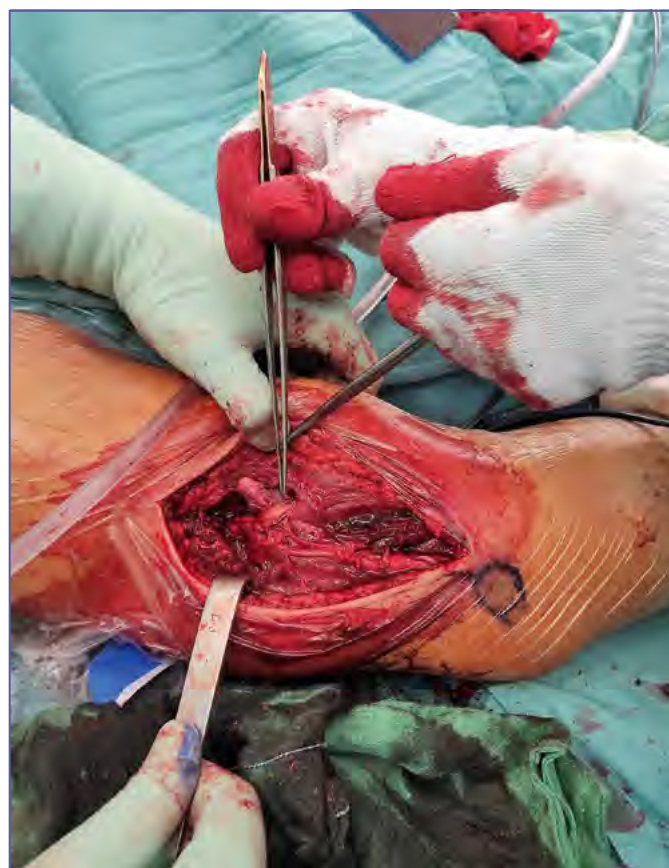**Figure 1.** Humeral distal fracture with radial nerve palsy. Pre-surgery X-ray.

For physical examination, radial nerve sensitivity with light touch and pinprick should be tested along of radial nerve course in the central part of dorsal forearm and in the hand (is easier) along the dorsal aspect of first interdigital space. Radial nerve motor function is evaluated by testing the active extension of the wrist and fingers including the thumb, in particular the metacarpophalangeal joint and not the proximal and distal interphalangeal joints. When the recovery of wrist extension occurs, the force of gravity must be eliminated in order to control the recovery<sup>2/5</sup>.

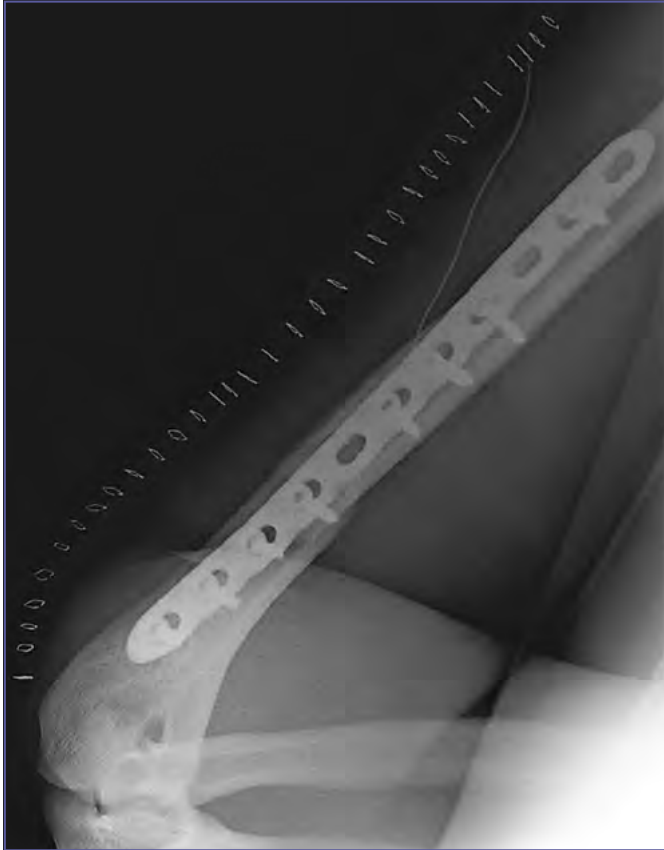
Distalization of Tinel's sign involves recovering innervated muscles progressively from the radial nerve with good precision. The brachioradialis muscle recovers first, and the extensor thumb longus last<sup>16</sup>.

Instrumental follow-up is performed by ultrasonography (US)<sup>24</sup> and electromyography (EMG). US has a sensitivity of 93% in identifying focal lesions of the nerve, and can investigate the structural integrity of the nerve<sup>24</sup>.

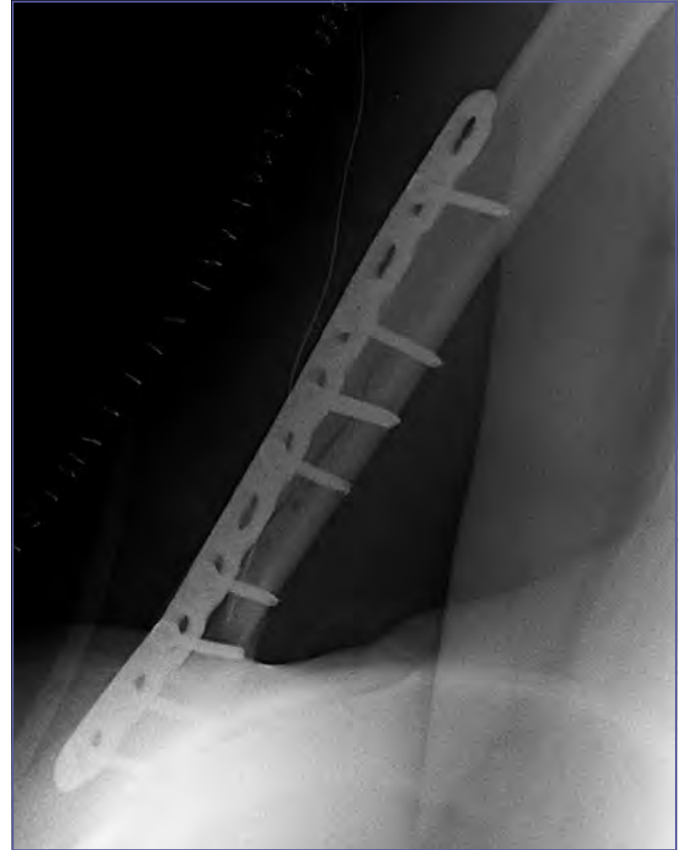These examinations do not have a role in the acute setting, but can be helpful to determine baseline nerve function after 4 weeks because this is usually the time required for pathologic potentials of muscle denervation to develop. If over more than 4 weeks fol-



**Figure 2.** Humeral distal fracture with radial nerve palsy, intra-operative clinical photo.



**Figure 3. Humeral distal fracture with radial nerve palsy, X-ray post-surgery LL.**



**Figure 4. Humeral distal fracture with radial nerve palsy, X-ray post-surgery AP.**

low-up EMG shows a polyphasic wave, meaning larger polyphasic motor unit action potentials of longer duration, this is indicative of an attempt at recovery, otherwise it is a negative prognostic factor. In addition to monitoring, it is useful to use a brace to avoid hand drop, electrostimulation<sup>25</sup> of denervated muscles, and the use of neurotrophic drugs/supplements<sup>26</sup>.

The first signs of spontaneous recovery are detectable after 50-60 days clinically or with an EMG in the first reinnervable muscle: the brachioradialis.

The timing provides for US, EMG, and clinical monitoring is every 4 weeks for to a maximum of 16 weeks. If a failure to recover persists, it is mandatory to refer the patient for microsurgery within a 4-6 months to undergo nerve grafting. If there is a only partial recovery after 6 months, tendon transfer<sup>27,28</sup> or nerve branch transfer<sup>29</sup> is the last chance if the nerve is irreparable<sup>5,27</sup>.

A delay of more of 12 months worsen the outcome, because motor endplates needs to be reinnervated within 12 months to restore useful function. Beyond 12 months irrecoverable muscle atrophy begins, and thus the timing of nerve repair is paramount.

## Conclusions

We believe that early surgical treatment of humeral fractures with neurological lesions is the correct strategy for several reasons. First of all, even in large trauma area, these lesions are rare over one year and can be dealt without particular problems. Moreover, “most” cases are not all cases. In our surgical experience, we have found nerves trapped by the fracture site, which would certainly have suffered further damage if they had not been released early. We have observed cases of dissected nerves or pierced by sharp bone specula. Thus, early exploration allows for characterization of nerve injury and treatment together with fracture stabilization and avoids late nerve incarceration (Figs. 2-4). Furthermore, early exploration permits repair that is expressed in a less motor endplate loss, less muscular atrophy, which leads to quicker nerve recovery and return to function. In conclusion, we always proceed with opening the fracture site to explore the nerve and open reduction and internal fixation with plate.

We believe that in open fractures with neurological deficits, early stabilization with an external fixator is necessary, as well as repair of the vascular damage when present, and careful ex-

ploration of the affected nerve with a plastic surgeon or micro surgeon.

In closed fractures with radial nerve paralysis, we believe immediate exploration, within 12 hours, and rigid osteosynthesis with a plate is warranted. Furthermore, from an economic point of view, a conservative approach is less expensive. However, if this perspective considers the primary treatment, with the costs of the secondary interventions of the lowering of the quality of life, as well as the costs of a prolonged rehabilitation, early exploration of nerve palsies is cost-effective<sup>30</sup>.

#### Conflict of interest statement

The authors declare no conflict of interest.

#### Funding

This research did not receive any specific grant from funding agencies in the public, commercial, or not-for-profit sectors.

#### Author contributions

AM, RP: have given substantial contributions to the study conception; AM, LG, RP: contributed to the manuscript critical revision for important intellectual content.

#### Ethical consideration

Not applicable.

#### References

- Pidhorz L. Acute and chronic humeral shaft fractures in adults. *Orthop Traumatol Surg Res* 2015;101:S41-S49. <https://doi.org/10.1016/j.otsr.2014.07.034>
- Karita Y, Kimura Y, Sasaki S, et al. Axillary artery and brachial plexus injury secondary to proximal humeral fractures: a report of 2 cases. *Int J Surg Case Rep* 2018;50:106-110. <https://doi.org/10.1016/j.ijscr.2018.04.044>
- Sumarwoto T, Hadinoto SA, Kaldani F, et al. The characteristic of 374 surgically treated traumatic brachial plexus injury patients at an Indonesian orthopedic referral hospital: an epidemiologic and sociodemographic view. *Orthop Res Rev* 2022;14:419-428. <https://doi.org/10.2147/ORR.S386142>
- Ng AJH, Arora V, Tang HHH, et al. Axillary artery injury associated with proximal humeral fractures: review of long-term vascular, orthopedic, and neurologic outcomes. *Ann Vasc Surg* 2016;33:210-219. <https://doi.org/10.1016/j.avsg.2015.10.038>
- Venouziou AI, Dailiana ZH, Varitimidis SE, et al. Radial nerve palsy associated with humeral shaft fracture. Is the energy of trauma a prognostic factor? *Injury* 2011;42:1289-1293. <https://doi.org/10.1016/j.injury.2011.01.020>
- Chang G, Ilyas AM. Radial nerve palsy after humeral shaft fractures: the case for early exploration and a new classification to guide treatment and prognosis. *Hand Clin* 2018;34:105-112. <https://doi.org/10.1016/j.hcl.2017.09.011>
- Mouraria GG, Mendonça BCN, Dias AL, et al. Epidemiological study of surgically treated humeral shaft fractures – a 10-year review. *Acta Ortop Bras* 2022;30:1-4. <https://doi.org/10.1590/1413-785220223006e256500>
- Schwab TR, Stillhard PF, Schibli S, et al. Radial nerve palsy in humeral shaft fractures with internal fixation: analysis of management and outcome. *Eur J Trauma Emerg Surg* 2018;44:235-243. <https://doi.org/10.1007/s00068-017-0775-9>
- Bercik MJ, Kingsbery J, Ilyas AM. Peripheral nerve injuries following gunshot fracture of the humerus. *Orthopedics* 2012;35:E349-E352. <https://doi.org/10.3928/01477447-20120222-18>
- Holstein A, Lewis GM. Fractures of the humerus with radial-nerve paralysis. *J Bone Joint Surg Am* 1963;45:1382-1388. <https://doi.org/10.2106/00004623-196345070-00004>
- Eckholm R, Ponzer S, Törnkvist H, et al. Primary radial nerve palsy in patients with acute humeral shaft fractures. *J Orthop Trauma* 2008;22:408-414. <https://doi.org/10.1097/BOT.0b013e318177eb06>
- Liu GY, Zhang CY, Wu HW. Comparison of initial nonoperative and operative management of radial nerve palsy associated with acute humeral shaft fractures. *Orthopedics* 2012;35:702-708. <https://doi.org/10.3928/01477447-20120725-10>
- Sonneveld GJ, Patka P, van Mourik JC, et al. Treatment of fractures of the shaft of the humerus accompanied by paralysis of the radial nerve. *Injury* 1987;18:404-406. [https://doi.org/10.1016/0020-1383\(87\)90287-7](https://doi.org/10.1016/0020-1383(87)90287-7)
- Yeh KL, Liaw CK, Wu TY, et al. Radial nerve recovery following closed nailing of humeral shaft fractures without radial nerve exploration: a retrospective study. *World J Clin Cases* 2021;9:8044-8050. <https://doi.org/10.12998/wjcc.v9.i27.8044>
- Keighley G, Hermans D, Lawton V, et al. Radial nerve palsy in mid/distal humeral fractures: is early exploration effective? *ANZ J Surg* 2018;88:228-231. <https://doi.org/10.1111/ans.14259>
- Noaman H, Khalifa AR, El-Deen MA, et al. Early surgical exploration of radial nerve injury associated with fracture shaft humerus. *Microsurgery* 2008;28:635-642. <https://doi.org/10.1002/micr.20542>
- Den Hartog D, van Bergen SH, Mahabier KC, et al. Functional and clinical outcome after operative versus non-operative treatment of a humeral shaft fracture (HUMMER): results of a multicenter prospective cohort study. *E J Trauma Emerg Surg* 2022;48:3265-3277. <https://doi.org/10.1007/s00068-022-01890-6>
- Seddon HJ. A classification of nerve injuries. *Br Med J* 1942;2:237-239. <https://doi.org/10.1136/bmj.2.4260.237>
- Sunderland S. A classification of peripheral nerve injuries producing loss of function. *Brain* 1951;74:491-516. <https://doi.org/10.1093/brain/74.4.491>
- Lowe JB; Sen SK, Mackinnon SE. Current approach to radial nerve paralysis. *Plast Reconstr Surg* 2002;110:1099-1112. <https://doi.org/10.1097/01.PRS.0000020996.11823.3F>
- Shao YC, Harwood P, Grotz MRW, et al. Radial nerve palsy associated with fractures of the shaft of the humerus: a systematic review. *J Bone Joint Surg* 2005;87:1647-1652. <https://doi.org/10.1302/0301-620X.87B12>
- Bumbaširević M, Lešić A, Bumbaširević V, et al. The management of humeral shaft fractures with associated radial nerve palsy: a review of 117 cases. *Arch Orthop Trauma Surg* 2010;130:519-522. <https://doi.org/10.1007/s00402-009-0951-4>
- Korompilias AV, Lykissas MG, Kostas-Agnantis IP, et al. Approach to radial nerve palsy caused by humerus shaft fracture: is

- primary exploration necessary? *Injury* 2013;44:323-326. <https://doi.org/10.1016/j.injury.2013.01.004>
- <sup>24</sup> Wijntjes J, Borchert A, van Alfen N. Nerve ultrasound in traumatic and iatrogenic peripheral nerve injury. *Diagnostics* 2021;11:30. <https://doi.org/10.3390/diagnostics11010030>
- <sup>25</sup> Elabd R, Alabdulkarim A, Alsbah S, et al. Role of electrical stimulation in peripheral nerve regeneration: a systematic review. *Plast Reconstr Surg Glob Open* 2022;10:E4115. <https://doi.org/10.1097/GOX.0000000000004115>
- <sup>26</sup> Hart AM, Terenghi G, Kellerth JO, et al. Sensory neuroprotection, mitochondrial preservation, and therapeutic potential of N-acetylcysteine after nerve injury. *Neuroscience* 2004;125:91-101. <https://doi.org/10.1016/j.neuroscience.2003.12.040>
- <sup>27</sup> Bevin AG. Early tendon transfer for radial nerve transection. *Hand* 1976;8:134-136. [https://doi.org/10.1016/0072-968x\(76\)90033-4](https://doi.org/10.1016/0072-968x(76)90033-4)
- <sup>28</sup> Kumar Vyas A, Gupta A, Patni P, et al. Evaluation of results of various tendon transfers in high and low radial nerve palsy. *J Clin Orthop Trauma* 2020;11:614-619. <https://doi.org/10.1016/j.jcot.2020.05.023>
- <sup>29</sup> Tian J, Leng M, Wang K, et al. Pronator teres nerve branch transfer to the extensor carpi radialis brevis nerve branch for wrist extension reconstruction in proximal radial nerve injury following humeral shaft fractures. *BMC Musculoskelet Disord* 2022;23:980. <https://doi.org/10.1186/s12891-022-05950-1>
- <sup>30</sup> van Bergen SH, van Lieshout EMM, Mahabier KC, et al. Economic evaluation of operative versus nonoperative treatment of a humeral shaft fracture: economic analyses alongside a multicenter prospective cohort study (HUMMER). *Eur J Trauma Emerg Surg* 2022;Dec 8. <https://doi.org/10.1007/s00068-022-02160-1> [Epub Ahead of Print]